

# Intracranial hemorrhages in pediatric age group in Babylon province

*Hemorragias intracraneales en el grupo de edad pediátrica en la provincia de Babilonia*

Ali Abbas Hashim Almusaw<sup>1</sup>, <https://orcid.org/0000-0001-7335-9055>, Nadia Riyadh Maaroo<sup>2</sup>, <https://orcid.org/0000-0003-3067-6629>

<sup>1</sup>lecturer, Hammurabi College of Medicine, University

<sup>2</sup>babylon health director

\*corresponding author: Ali Abbas Hashim Almusaw, lecturer, Hammurabi College of Medicine, university. Email: [aliabbasalmusawi@gmail.com](mailto:aliabbasalmusawi@gmail.com)

Received/Recibido: 05/12/2020 Accepted/Aceptado: 06/15/2020 Published/Publicado: 07/20/2020

221

## Abstract

**Introduction:** intracranial bleeding is abnormal accumulation of blood inside the vault of cranium it may occur inside the brain parenchyma as intracerebral bleeding or covering the meningeal space. The aim of study to shed a light on the most common cause of mortality among pediatric patients with intracranial hemorrhage.

**Method:** a cross-sectional study on 45 patients with intracranial hemorrhages age (1day - 1years) admitted to Pediatric Intensive Care Unit at Babylon maternity and pediatric teaching hospital in a Babylon province during the period between (1st May 2018 - 1st May 2019), consisting of (29 male) and (16 female).

**Results:** regarding the types of intracranial hemorrhages and their percentages we found only one patient with EDH (2.22%) from the total number of patients (45), SDH only (14) patients about (31.11%), SAH (4) patients (8.88%), ICH intracerebral hemorrhage (3) patients (6.66%), IVH (4) patients (8.88), we have also three patients with mixed SDH and SAH representing (6.66%), SAH with IVH only in two patients (4.44%), SDH with IVH in three patients (6.66%), SDH with ICH in four patients (8.88%), ICH with SAH in only two patients (4.44%), and lastly ICH with IVH in five patients (11.11%). so from previous descriptions of the types of ICH percentages we found that SDH a count for about (31.11%) of the hemorrhages. Regarding the total serum bilirubin TSB found that it increased more than 15 mg/dL in 50% of dead patients and prolong PTT, PT compromise (72.22%) of mortality.

**Conclusion:** the prolongation in bleeding profile PT, PTT, birth trauma, and elevated TSB and associated congenital anomalies like CHD, Ddown syndrome are associated with increased risk of mortality in pediatric patients with intracranial hemorrhage.

**Keywords:** Intracranial hemorrhages, Pediatric age group, Babylon province.

## Resumen

**Introducción:** El sangrado intracraneal es una acumulación anormal de sangre dentro de la bóveda del cráneo que puede ocurrir dentro del parénquima cerebral como sangrado intracerebral o que cubre el espacio meníngeo. El objetivo del estudio es arrojar una luz sobre la causa más común de mortalidad entre los pacientes pediátricos con hemorragia intracraneal.

**Método:** un estudio transversal en 45 pacientes con hemorragias intracraneales de edad (1 día - 1 año) ingresados en la Unidad de Cuidados Intensivos Pediátricos en el hospital de maternidad y enseñanza pediátrica de Babylon en una provincia de Babilonia durante el período comprendido entre (1 de mayo de 2018 - 1 de mayo de 2019), compuesto por (29 hombres) y (16 mujeres).

**Resultados:** con respecto a los tipos de hemorragias intracraneales y sus porcentajes, encontramos un solo paciente con EDH (2.22%) del número total de pacientes (45), solo con SDH (14) pacientes (31.11%), pacientes con SAH (4) ( 8,88%), pacientes con hemorragia intracerebral ICH (3) (6,66), pacientes con Hiv (4) (8,88), también tenemos tres pacientes con SDH y SAH mixtos (6,66%), HSA con IVH solo en dos pacientes (4,44% ), SDH con IVH en tres pacientes (6.66%), SDH con ICH en cuatro pacientes (8.88%), ICH con SAH en solo dos pacientes (4.44%), y finalmente ICH con IVH en cinco pacientes (11.11%). Entonces, a partir de descripciones previas de los tipos de porcentajes de ICH, encontramos que SDH es un recuento de aproximadamente (31.11%) de las hemorragias. Con respecto a la bilirrubina sérica total, TSB encontró que aumentó más de 15 mg / dL en el 50% de los pacientes muertos y prolonga el PTT, compromiso de PT (72,22%) de la mortalidad.

**Conclusión:** la prolongación del perfil hemorrágico PT, PTT, trauma de nacimiento y TSB elevada y anomalías congénitas asociadas como CHD, síndrome de Down están asociadas con un mayor riesgo de mortalidad en pacientes pediátricos con hemorragia intracranial.

**Palabras clave:** Hemorragias intracraneales, grupo de edad pediátrica, provincia de Babilonia

Intracranial bleeding is abnormal accumulation of blood inside the vault of cranium it may occur inside the brain parenchyma as intracerebral bleeding or covering the meningeal space<sup>1</sup>. Bleeding inside meninges or related spaces, consist of epidural hematoma, hematoma subdural and bleeding inside ventricles and subarachnoid bleeding<sup>2,3</sup>. The abnormalities include trauma as injury of head, unusual blood vessels inside brain, unusual development of blood vessels (arteriovenous deformity)<sup>4</sup>, swelling inside the wall of vessel inside the brain (aneurysm), debilitated vessels due to some types of tumor<sup>5</sup>, sickle cell illness, genetic bleeding difficulties or liver difficulties<sup>6</sup>. Symptoms of intracranial bleeding include: abrupt, acute headache, dizziness or collapsing, abnormal vision, talking, or movement, misperception, life-threatening irritability, or rapid behavior alteration, or unconsciousness, high temperature, rigid neck, seizures, nausea besides vomiting, identifies of intracranial bleeding occur by MRI or CT image. All these give full description about the brain by assessed if any hemorrhage by used contrast like fluid that make vessels simply to show<sup>7</sup>. While angiography is test by passing catheter inside the vessels to reach the brain and through this catheter, dyes sent and make the vessels easy to recognize<sup>8</sup>. This manouvour can easily to done by MRA (magnetic resonance angiography)<sup>9,10</sup>.

Transcranial Doppler (TCD) this method show the blood inside vessels that reach to brain, innocent (harmless) sound waves to create image to brain and vessels to screen continuing disorders that may deteriorate the hemorrhage. About the laboratory tests, blood used to test any danger reasons like counts of platelets and clotting factors test<sup>11</sup>. Management depend on reason, extent, and site of the hemorrhage. The treatment depends on kid's well-being situation. Management can consist of; 1. Remark. Minor quantities of hemorrhage will reabsorb obviously and does not need operation, using medical treatment to stop hemorrhage, control seizures and normalize blood pressure. 2. Operation, eliminate stuck blood or additional liquid in the brain, reparation of unusual vessels in the brain. Otherwise, a tube can be used to insertion glue, a loop, or a balloon into the unusual vessel this is very important to stop moreover hemorrhage. Additional kids may have continuing neurologic difficulties include suffering in education, talking, or effort and seizures so need to management that is more careful from physician<sup>12</sup>. The aim of study is to shed a light on the most common cause of mortality among pediatric patients with intracranial hemorrhage.

This is a cross-sectional study was conducted on 45 patients with intracranial hemorrhages age (1day-1years) admitted to pediatric intensive care Unit at Babylon maternity and pediatric teaching hospital in a Babylon province during the period between (1st May 2018 - 1st May 2019), consisting of (29 male) and (16 female), medical records were evaluated retrospectively. Data collected included age, gender, TSB, history of bleeding tendency, history of birth trauma, type of ICH. Laboratory studies include blood aspiration (5 ml) from all patients to estimate a complete blood count, urine analysis, TSB (Total Serum Bilirubin) and determination of (PTT, PT) partial thromboplastin Time, Prothrombin Time), abdominal ultra-sonography, CXR chest X-ray, echocardiography and brain CT scan done to determine the anatomical location of hemorrhages. Statistical analysis done by SPSS 22 for categorical variables use frequency and percentage, Chi-square and Fischer exact tests to show association between categorical variables. The P-value considered significant if less than 0.05.

Cross sectional study of 45 patients, as in table (1) we divide our patients to the three groups according to their ages: 1st group include those (1-28) days their mean age  $\pm$  SEM equals to  $(3.71 \pm 1.36)$  days and they are (14 patients). Second group includes those (1-6) months their mean age  $\pm$  SEM equals to  $(1.82 \pm 0.17)$  months and they are (28 patients). Third group includes those (6-12) months their mean age  $\pm$  SEM equals to  $(11.66 \pm 0.32)$  months and they are (3) patients.

Table (1) the mean age of the patients

Age	Mean $\pm$ SEM	Total numbers of patients	Percentage %
1-28 days	3.71 $\pm$ 1.36	14	31.11
1-6 months	1.82 $\pm$ 0.17	28	62.22
6 months-1 year(12 Mo)	11.66 $\pm$ 0.32	3	6.66

Regarding the gender of the patients, 64.44 % of patients were male and 35.55 % were female, 18 (40%) patients died and 27 (60%) patients a life, while life male 70% and life female are 30% of total life patients as in table 2.

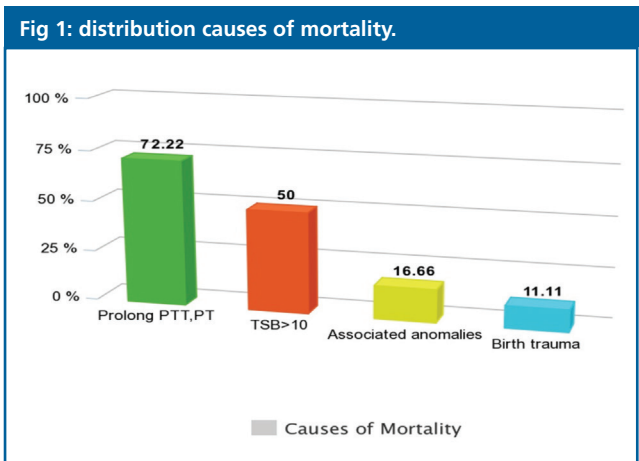
Variables		Frequency	Percentage
Gender	Male	29	64.44%
	Female	16	35.55%
Outcome	Life	27	60%
	Dead	18	40%
Life male		19	70%
Life female		8	30%
dead male		10	55%
dead female		8	45%

regarding the types of intracranial hemorrhages and their percentages we found only one patient with EDH (2.22%) from the total number of patients (45), SDH only (14) patients about (31.11%), SAH (4) patients (8.88%), ICH intracerebral hemorrhage (3) patients (6.66%), IVH (4) patients (8.88), we have also three patients with mixed SDH and SAH representing (6.66%),

SAH with IVH only in two patients (4.44%), SDH with IVH in three patients (6.66%), SDH with ICH in four patients (8.88%), ICH with SAH in only two patients (4.44%), and lastly ICH with IVH in five patients (11.11%). so from previous descriptions of the types of ICH percentages we found that SDH a count for about (31.11%) of the hemorrhages. Regarding the total serum bilirubin TSB was found that it increased more than 15 mg/dL in 50% of dead patients and prolong PTT, PT compromise (72.22%) of mortality as show in table 3.

Regarding the associated anomalies we find only three of the dead patients have the following anomalies; one has Congenital Heart Disease (CHD), one has Rib's anomaly and one has Down syndrome so the associated anomalies account about (16.66%) of mortality. Prolong labor with birth trauma found only in two died patients and account about (11.11%) of mortality as in figure (1).

Types of intracranial hemorrhages	Number of patients	% of intracranial hemorrhages types
EDH	1	2.22
SDH	14	31.11
SAH	4	8.88
ICH	3	6.66
IVH	4	8.88
SDH +SAH	3	6.66
SAH +IVH	2	4.44
SDH +IVH	3	6.66
SDH +ICH	4	8.88
ICH+SAH	2	4.44
ICH+IVH	5	11.11



Discussion

ICH is a spontaneous extravasation of blood into the brain parenchyma that may also extend into the ventricles or subarachnoid space<sup>13</sup>. Intracranial hemorrhage (ICH) in children often causes death or lifelong disability. In this study, prolonged PTT, PT and elevated TSB levels accounted for a greater proportion of mortality ICHs. The early laboratory assessment of a kid with a supposed hemorrhage sickness should take in a whole blood cell amount, prothrombin time (PT), activated partial thromboplastin time (a PTT). Elongation of PT besides a PTT in children with no symptoms occur due to many serious factors a usual reason for elongation clotting times is mistake in gaining sufficient quantity of blood or postponement in treating the blood tasters and these not happen in current study. Lupus anticoagulants may lead to viral contamination and lead to elongated PT and a PTT with no hemorrhage, in current study no any infection occur<sup>14-16</sup>.

PT and a PTT are more usual test for assessment coagulation problems, elongation of them occur in coagulation elements lack (antibody in contradiction of a clotting element)<sup>17</sup>. Laboratory assessment in vitamin K absence exposes prolonged PT besides a PTT with standard platelets in addition to fibrinogen level. Vit. K give direct subcutaneously to infant with hemorrhage, while giving Vit. K through intravenous lead to infrequent anaphylactic responses all this route of management can accurate PT within 4 hours. While giving Vit. K by mouth can delay response to 8 hours if absorbed well. (FFP) fresh frozen plasma give with Vit K if any risk of hemorrhage in child. Full term baby should take 1 mg of intramuscular vitamin K at natal (0.3 mg if weight less than 1 Kg and 0.5 mg if weight more than 1 Kg as a defensive maneuver. The most common causes of spontaneous ICH in children are found to be vascular malformations like arteriovenous malformations (AVM), aneurysms, and cavernous angio-ma<sup>18</sup>. These account for almost 40% to 57% of cases of spontaneous ICH but in our study, we found that prolong PTT, PT account for about (72.22%) of mortality of intracranial hemorrhages. Total serum bilirubin more than (15mg) was found in (50%) of mortality as the increased total serum, bilirubin can be caused by unusual blood cell

forms (sickle cell anemia), blood incompatibility between baby and mother, hematoma under the scalp occur by any damage during delivery, increase RBCs all these is very common in small foe age baby and twins. Deficiency in definite important enzymes but in our study we find only one patients has history of birth trauma accounting for about (11.11) from mortality. Other causes that also lead to more severe increase in TSB, including: Certain medicines, Infections present at birth, such as rubella, syphilis, and others Diseases that affect the liver or biliary tract, such as cystic fibrosis or hepatitis, Low oxygen level (hypoxia) Infections (sepsis) Many different genetic or inherited disorders. Babies who are born too early (premature) are more likely to develop increased level of total serum bilirubin than full-term babies. Down syndrome occur due to abnormality in chromosome 21, linked with installation of huge quantities of amyloid inside the essential nervous system. It occur in two ways: plaques inside the brain parenchyma besides in walls of vessels cerebellum, the precursor of amyloid protein (APP) gene lies on chromosome 21 and its presence in three copies in DS Down syndrome and the intracerebral hemorrhage, the main clinical consequence of vascular amyloidosis<sup>19,20</sup>. In our study the associated anomalies which are Down syndrome, Ribs anomaly and congenital heart disease CHD account for about (16.67%) of mortality. Ribs anomalies has been also reported as a case report by Chowdareddy N. and in this reported case the chest examination revealed widening of the rib spaces between 3 rd and 5th on right side with bony prominence at the same region<sup>21</sup>. Regarding the CHD recent literature describing brain abnormalities in this population with CHD primarily focused on white matter injury, stroke, and alterations in brain development as key pathways for subsequent neurodevelopmental impairment<sup>22-26</sup>, intraventricular hemorrhage (IVH) is in particular concern when infants with CHD are born preterm. IVH can have significant ramifications for long-term neurodevelopmental outcomes, but in our study the patients with CHD is full term and died accounting about (5.5%) of mortality<sup>27,28</sup>.

## Conclusions

**T**he prolongation in bleeding profile PT, PTT, birth trauma, and elevated TSB and associated congenital anomalies like CHD, down syndrome are associated with increased risk of mortality in pediatric patients with intracranial hemorrhage.

## References

1. Rom S, Serfontein GL, Humphreys RP. Intracerebellar Hematoma in the Neonate. *J Pediatr*. 1978; 93:486–488
2. Volpe JJ. Neonatal Intraventricular Hemorrhage. *N Engl J Med*. 1981; 304:886–891
3. Dykes FD, Lazzara A, Ahmann P, et al. Intraventricular Hemorrhage: A Prospective Evaluation of Etiopathologies. *Pediatrics*. 1980; 66: 42–49
4. Pasqualin A, Barone G, Cioffi F, et al. The relevance of anatomic and hemodynamic factors to a classification of cerebral arteriovenous malformations. *Neurosurgery*. 1991; 28:370–379
5. Chugani HT, Rosemblat AM, Lavenstein BL, et al. Childhood Medulloblastoma Presenting with Hemorrhage. *Childs Brain*. 1984; 11:135–140
6. Toffol GJ, Biller J, Adams HP. Nontraumatic Intracerebral Hemorrhage in Young Adults. *Arch Neurol*. 1987; 44:483–485
7. Laissy JP, Normand G, Monroc M, et al. Spontaneous Intracerebral Hematomas from Vascular Causes: Predictive Value of CT Compared with Angiography. *Neuroradiology*. 1991; 33:291– 295
8. Zhu XL, Chan MSY, Poon WS. Spontaneous Intracranial Hemorrhage: Which Patients Need Diagnostic Cerebral Angiography? A Prospective Study of 206 Cases and Review of the Literature. *Stroke*. 1997; 28:1406–1409
9. Zhu XL, Chan MSY, Poon WS. Spontaneous Intracranial Hemorrhage: Which Patients Need Diagnostic Cerebral Angiography? A Prospective Study of 206 Cases and Review of the Literature. *Stroke*. 1997; 28:1406–1409
10. Bradley WG. MR Appearance of Hemorrhage in the Brain. *Radiology*. 1993; 189:15–26
11. Martin NA, Doberstein C, Zane C, et al. Posttraumatic Cerebral Arterial Spasm: Transcranial Doppler Ultrasound, Cerebral Blood Flow, and Angiographic Findings. *J Neurosurg*. 1992; 77:575–583
12. Armstrong-Wells J, Johnston SC, Wu YW, et al. Prevalence and predictors of perinatal hemorrhagic [192] stroke: results from the Kaiser Pediatric Stroke Study. *Pediatrics*. 2009; 123:823–828
13. Mayer SA, Rincon F. Treatment of intracerebral haemorrhage. *Lancet Neurol* 2005;4(10):662–72.
14. Andrew M, Paes B, Milner R, et al. Development of the human coagulation system in the full-term infant. *Blood*. 1987;70(1):165–172.
15. Andrew M, Paes B, Milner R, et al. Development of the human coagulation system in the healthy premature infant. *Blood*. 1988;72(5):1651–1657.
16. Andrew M, Paes B, Johnston M. Development of the hemostatic system in the neonate and young infant. *Am J Pediatr Hematol Oncol*. 1990;12(1):95–104.
17. Kamal AH, Tefferi A, Pruthi RK. How to interpret and pursue an abnormal prothrombin time, activated partial thromboplastin time, and bleeding time in adults. *Mayo Clin Proc*. 2007;82:864–873.
18. W. D. Lo, J. Lee, J. Rusin, E. Perkins, and E. S. Roach, "Intracranial hemorrhage in children: an evolving spectrum," *Archives of Neurology*, vol. 65, no. 12, pp. 1629–1633, 2008.
19. Vinters HV, Gilbert JJ: Cerebral amyloid angiopathy: incidence and complications in the aging brain. II. The distribution of amyloid vascular changes. *Stroke*. 1983;14(6):924–8.



20. Pezzini A, Del Zotto E, Volonghi I, et al.: Cerebral amyloid angiopathy: a common cause of cerebral hemorrhage. *Curr Med Chem.* 2009;16(20):2498–513.
21. Chowdareddy N1\*, Anil Kumar Y.C1, Nouseed Ani2, Gopal K3, Isolated Bifid Rib with Intracranial Hemorrhage in a Neonate: Case Report, *Scholars Journal of Applied Medical Sciences (SJAMS) Sch. J. App. Med. Sci.*, 2014; 2(1C):251-252.
22. Rollins, C. K. et al. White Matter Volume Predicts Language Development in Congenital Heart Disease. *Journal of Pediatrics* 181, 42-48.e2 (2017).
23. Beca J, Gunn JK, Coleman L, et al. New white matter brain injury after infant heart surgery is associated with diagnostic group and the use of circulatory arrest. *Circulation.* 2013;127:971–979.
24. Cheng HH, Rajagopal S, McDavitt E, et al. Stroke in Acquired and Congenital Heart Disease Patients and Its Relationship to Hospital Mortality and Lasting Neurologic Deficits. *Pediatr Crit Care Med.* 2016;17:976–983.
25. von Rhein M, Buchmann A, Hagmann C, et al. Brain volumes predict neurodevelopment in adolescents after surgery for congenital heart disease. *Brain.* 2014;137:268–276.
26. Andropoulos DB, Ahmad HB, Hag T, et al. The association between brain injury, perioperative anesthetic exposure, and 12-month neurodevelopmental outcomes after neonatal cardiac surgery: a retrospective cohort study. *Paediatr Anaesth.* 2014;24:266–274.
27. Davis AS, Hintz SR, Goldstein RF. Outcomes of extremely pre-term infants following severe intracranial hemorrhage. *J Perinatol.* 2014;34:203–208.
28. Mukerji A, Shah V, Shah PS. Periventricular/Intraventricular Hemorrhage and Neurodevelopmental Outcomes: A Meta-analysis. *Pediatrics.* 2015;136:1132–1143



[www.revhipertension.com](http://www.revhipertension.com)  
[www.revdiabetes.com](http://www.revdiabetes.com)  
[www.revsindrome.com](http://www.revsindrome.com)  
[www.revistaavft.com](http://www.revistaavft.com)

#### Indices y Bases de Datos:

AVFT está incluida en las bases de datos de publicaciones científicas en salud:

**OPEN JOURNAL SYSTEMS**

**REDALYC** (Red de Revistas Científicas de América Latina, el Caribe, España y Portugal)

**SCOPUS** de Excerpta Medica

**GOOGLE SCHOLAR**

**Scielo**

**BIREME** (Centro Latinoamericano y del Caribe de Información en Ciencias de la Salud)

**LATINDEX** (Sistema Regional de Información en Línea para Revistas Científicas de América Latina, el Caribe, España y Portugal)

**Índice de Revistas Latinoamericanas en Ciencias** (Universidad Nacional Autónoma de México)

**LIVECS** (Literatura Venezolana de Ciencias de la Salud)

**LILACS** (Literatura Latinoamericana y del Caribe en Ciencias de la Salud)

**PERIÓDICA** (Índices de Revistas Latinoamericanas en Ciencias)

**REVENCYT** (Índice y Biblioteca Electrónica de Revistas Venezolanas de Ciencias y Tecnología)

**SABER - UCV**

**EBSCO Publishing**

**PROQUEST**