

Evaluation of Functional Risk Area by Myocardial Strain Analysis in Unstable Angina

Avaliação da Área de Risco Funcional pela Análise do Strain Miocárdico na Angina Instável

Pedro Henrique Albuquerque¹, José Maria Del Castillo², Luciano Borba¹, Carlos Romério Ferro^{1,3}, Cyro Cabral Júnior³, Antônio Everaldo Filho¹, Ricardo César Cavalcanti¹

¹Heart Hospital of Alagoas, Alagoas, Brazil; ²ECOPE (Pernambuco School of Ultrasound), Recife, Pernambuco, Brazil; ³Federal University of Alagoas (UFAL), Maceió, Alagoas, Brazil.

Introduction

Although fundamental for the early risk stratification of patients with chest pain, electrocardiography has limited capacity to detect acute coronary syndrome with a sensitivity of 70%.¹ Acute myocardial ischemia can induce left ventricular systolic dysfunction,² which can be quantified by echocardiography (ECHO). The strain technique is a highly accurate manner to estimate the regional systolic function of the left ventricle (LV), which changes even before visualization in the two-dimensional analysis of myocardial contractility.³ The left ventricular longitudinal strain (LVLS) speckle tracking method, which analyzes myocardial deformation, is a very sensitive tool for detecting ischemia.⁴

The ischemic risk area (IRA) is the myocardial region with a perfusion deficit. The absent or low coronary flow that delimits the IRA is assessed by perfusion image acquisition with computed tomography or contrast ECHO.⁵ However, these examinations are not available in the emergency department of most hospitals. For this study, the functional risk area by strain was analyzed. Experimental studies showed an excellent correlation between IRA and regional dysfunction area by strain.^{4,5}

This study aimed to test the ability of LVLS to predict severe obstructive coronary artery disease (luminal obstruction greater than 70%) in patients with chest pain or equivalent ischemic symptoms and normal myocardial contractility when analyzed by conventional two-dimensional ECHO (2D-ECHO).

Methods

This cross-sectional study was conducted in a single tertiary heart care center. A total of 20 patients were sequentially included between April and February 2019. The inclusion criteria were a clinical diagnosis of unstable angina in the emergency department, planned coronary angiography within three days after inclusion in the study, and normal myocardial contractility on a 2D-ECHO before catheterization. The

Keywords

Strain; Ischemia; Unstable Angina.

Mailing Address: Pedro Henrique Albuquerque • Hospital do Coração de Alagoas, Avenida Ariosvaldo Pereira Cintra, 152, Gruta de Lourdes. CEP: 57052-580, Maceió, AL, Brazil. E-mail: ph_albuquerque@yahoo.com.br Manuscript received 11/25/2019; revised 11/26/2019; accepted 3/31/2020

DOI:

exclusion criteria were a previous history of coronary disease, non-sinus rhythm, evidence of ST-elevation myocardial infarction on any electrocardiograph from admission to coronary angiography, elevated myocardial necrosis marker enzymes (troponin T > 0.40 ng/L or creatine kinase-MB > 24 IU/L), left bundle branch block (QRS > 120 ms), moderate or severe heart valve disease, previous cardiac surgery, renal failure treated with dialysis, and moderate or severe myocardial hypertrophy. The demographic characteristics and echocardiographic variables of patients in the catheterization groups with or without severe obstructive coronary artery disease (CAD) are shown in Table 1.

This study was approved by the ethics and research committee of the Heart Hospital of Alagoas. All procedures involved in this study were performed in accordance with the Helsinki Declaration of 1975 updated in 2013.

Echocardiography

The examinations were performed by a single observer using a Vivid E9 ultrasound system (GE Vingmed, Horten, Norway). Three consecutive cycles in three apical planes (four chambers, three chambers, and two chambers) were obtained by 2D-ECHO. The left ventricular ejection fraction was calculated using the Simpson method.

The longitudinal strain was acquired by the speckle tracking technique using automated functional imaging of three clips

Table 1 - Patient characteristics.

Characteristic	Normal catheterization (n = 9)	Changed catheterization* (n = 11)
Age, years	59.1	62.5
Sex		
Male	3	6
Female	6	5
LVEF, %	60.6	59
LVDD, mm	49.4	51.2
LAV, mL/m ²	29.2	31.1
Espessura das paredes do VE, mm		
Septum	9.2	9.5
PW	9.1	9.2

*One or more vessels with luminal obstruction greater than 70%. LVEF, ejection fraction on two-dimensional echocardiography using the Simpson method. LVDD, final left ventricular diastolic diameter. LAV, left atrial volume. PW, posterior wall of the left ventricle.

Brief Communication

with LV images in the 17 myocardial segments model. The endocardial borders were drawn on the end-diastolic 2D images of the three apical planes with effort made to ensure that all myocardial segments were well visualized. Aortic valve opening and closing events were marked. The images were acquired with a 45–80-fps frame rate. The values of each segment were calculated to acquire the mean LVLS value. Patients who had more than two inadequate segments for strain calculation were excluded from the study.

Functional risk area by strain

The functional risk area by strain is the area of the LV with a longitudinal strain change. The identification of dysfunction by strain analysis requires the establishment of a discriminatory cutoff value between the normal and abnormal segments. Therefore, the value of 15% was used to identify the segment with strain dysfunction. Deformation equal to or less than 15% in three or more contiguous segments on the bullseye LVLS analysis was characterized as the presence of a functional risk area.⁵

Statistical analysis

The variables are presented as mean and standard deviation (SD) or median (interquartile range [IQR]). The data were analyzed using RStudio software version 1.0.153. The normality of the residuals (Shapiro-Wilk test) was verified using the Nortest package. The mean LVLS value and the functional risk area by strain were compared using a receiver operating characteristic (ROC) curve and sensitivity and specificity were used to identify the ideal cutoff point. The pROC package was used to compare these curves.

Results

Clinical and angiography findings

Coronary angiography showed that 11 patients (55%) had CAD. Three-vessel disease (right coronary, anterior descending

and branches, circumflex and branches) was found in three patients (15%). Bilateral arterial disease was found in six patients (30%) and unilateral arterial disease in two patients (10%). Nine patients (45%) presented no major coronary obstructions (Table 2). A typical example of a patient with coronary disease and a large area of functional risk by strain is shown in Figure 1.

Analysis of the functional risk area

The functional risk area assessed by LVLS with a minimum of three segments showed a sensitivity of 81.8% and specificity of 88.9% for detecting CAD in symptomatic patients (Figure 2), a similar result to the global mean LVLS value with a cutoff point of 18.1% used to differentiate normal from pathological. In this study, of the 13 patients with a functional risk area by strain, 11 presented with a severe coronary obstruction on angiography. Although the sensitivity and specificity values are similar for both diagnostic methods (global LVLS and functional area), the functional area method presented greater accuracy than LVLS. However, comparison of the two ROC curves using the DeLong⁶ method showed no significant difference between these methods ($p = 0.255$).

Table 3 shows the characteristics of the 20 patients in the global LVLS value, number of contiguous segments with a strain inferior to 15%, and number of coronary arteries affected by a lumen obstruction greater than 70% (considering the anterior descending, circumflex, and right coronary artery).

Table 2 – Coronary arteries with more than 70% luminal obstruction.

Number of affected	n (%)
None	9 (45)
One	2 (10)
Two	6 (30)
Three	3 (15)

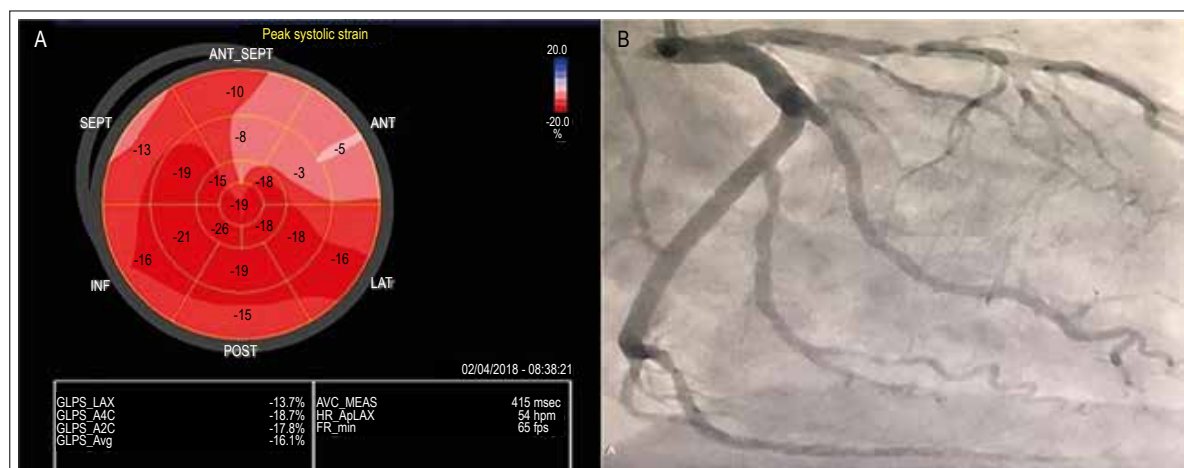


Figure 1 – Left – Bullseye showing a decreased global LVLS value (16.1%); functional risk area composed of six contiguous segments on the anteroseptal walls (pinkish and light red segments). Right – Coronary angiography in the right anterior oblique (RAO) view showing a severe obstructive lesion in the proximal third of the anterior descending coronary artery and a moderate injury in the proximal third of the second marginal circumflex branch.

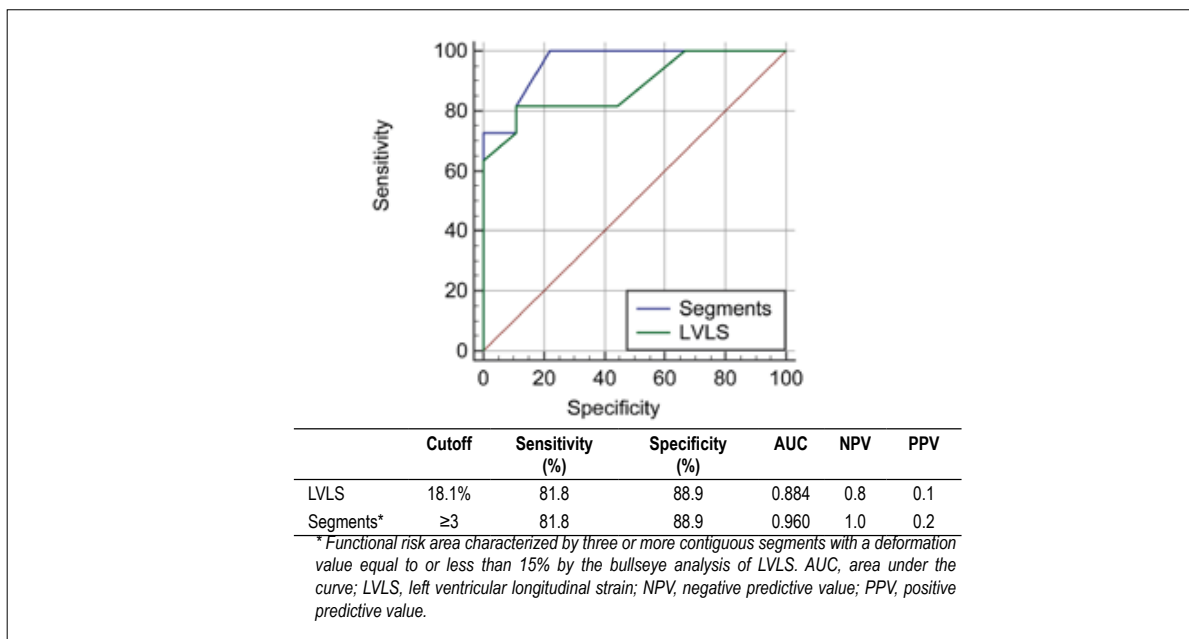


Figura 2 – Comparison of sensitivity and specificity of left ventricular longitudinal strain (LVLS) and functional risk area.

Comparison of LVLS and the number of contiguous segments with a strain inferior to 15% regarding the presence or absence of CAD revealed a significant intergroup difference ($p < 0.05$) (Table 4). Catheterized patients without CAD presented a mean LVLS value of $21.7\% \pm 2.3$ and 1.2 ± 1.8 affected contiguous segments; patients with CAD presented with an LVLS = $16.8\% \pm 2.9$ and 7.1 ± 3.3 affected contiguous segments.

Discussion

Patients with unstable angina commonly present global and regional systolic function changes by LVLS. The association of the analysis of functional risk area to other echocardiographic measures of myocardial systolic function makes ECHO an even more valuable tool for stratifying the risk of non-STE elevation acute coronary syndrome.

The strategy of including at least three contiguous LV segments with a strain inferior to 15% identified CAD patients with high sensitivity and specificity. This study showed a significant association between an extensive area with systolic dysfunction assessed by the strain method (functional risk area) and CAD.

Santos et al.⁷ studied the behavior of the myocardial strain in unstable angina but did not assess the functional risk area by segmental LVLS analysis. This strain area has a different interpretation from the global analysis with different cutoff points for normality. Unlike the studies of Eek et al.⁵ and Santos et al.⁷, this study analyzed the functional risk area by strain only in patients with unstable angina and without myocardial contractility changes on 2D-ECHO.

The most important finding in this study is that, in patients

Table 3 – global lvls value x important coronariopathy x functional risk area.

Contiguous segments with strain < 15%	Number of obstructed coronary arteries > 70%	Left ventricular longitudinal segment
0	0	25.2
0	0	24.0
0	0	23.2
0	0	22.6
0	0	21.2
1	0	17.8
2	0	20.5
3	0	21.0
3	2	18.1
3	3*	21.2
4	2	22.6
5	0	19.8
6	1	16.1
6	2	16.2
7	1	15.0
7	2	17.8
9	2	15.1
9	3	15.3
10	2	14.1
14	3	13.6

*Patient with major left coronary artery obstruction and major right coronary injury, an important obstruction of the three coronary arteries.

Brief Communication

Table 4 – LVLS x contiguous segments with reduced strain.

	Cate without CAD	Cate with CAD	P value
LVLS	21.7 ± 2.3	16.8 ± 2.9	<0.001*
Segments**	1.2 ± 1.8	7.1 ± 3.3	<0.001†

[†]Student's t-test ($p < 0.05$). [‡]Mann-Whitney U-test ($p < 0.05$). aMean ± standard deviation. CAD, coronary artery disease; Cate, coronary catheterization; LVLS, left ventricular longitudinal strain. **Number of contiguous segments with strain < 15%.

with unstable angina, the presence of CAD changes the regional and global LV systolic function by longitudinal strain assessment. Comparison with the global LVLS value showed that the functional risk area has better sensitivity as evidenced by the greater ROC area and better specificity as shown by its greater negative predictive power.

Limitations

As all patients were in sinus rhythm, these results cannot be extrapolated to patients with atrial fibrillation or other arrhythmias.

Several mechanisms can explain large areas of systolic dysfunction by strain, so it is important to perform a detailed anamnesis to assess other heart diseases that may present LVLS changes, such as myocardial hypertrophy, infiltrative cardiomyopathy, and heart valve disease. These patients generally present with uniformly depressed LV function and extensive involvement of the walls, sometimes the entire LV.

Since this is a cross-sectional observational study, the patients evaluated in the emergency department received individualized anti-ischemia pharmacological treatment, which may have influenced the final result of the strain. In the present study, all patients presenting with CAD on the

catheterization also presented with functional risk area by strain (Table 3).

The electrocardiography was performed in the emergency department and was not repeated immediately before the ECHO, so it is not possible to state whether the patient had a branch block or intermittent fascicular block at the time of the examination, which could have also changed the final result of the strain.

The low statistical power observed in this study is due to its limited number of patients and single-center setting.

Conclusion

LVLS is changed in patients with symptomatic CAD despite no presentation of segmental contractility abnormalities on 2D-ECHO.

Patients with unstable angina presented a significant association between functional risk area and CAD with high sensitivity and specificity. Thus, future studies with a greater number of patients are required to validate this method.

Author contribution

Research concept and design: Albuquerque PH. Data collection: Albuquerque PH, Borba L, Everaldo Filho A, Cavalcanti RC. Data analysis and interpretation: Albuquerque PH, Del Castillo JM. Statistical analysis: Albuquerque PH, Cabral Júnior C. Manuscript writing: Albuquerque PH, Del Castillo JM, Ferro CR. Critical revision of the manuscript: Del Castillo JM.

Conflict of interest

The authors have declared that they have no conflict of interest.

References

- Pettersson J, Pahlm O, Carro E, Edenbrandt L, Ringborn M, Sörnmo L, et al. Changes in high-frequency QRS components are more sensitive than ST-segment deviation for detecting acute coronary artery occlusion. *J Am Coll Cardiol.* 2000;36(6):1827-34.
- Theroux P, Franklin D, Ross J Jr, Kemper WS. Regional myocardial function during acute coronary artery occlusion and its modification by pharmacologic agents in the dog. *Circ Res.* 1974;35(6):896-908.
- Urheim S, Edvardsen T, Torp H, Angelsen B, Smiseth OA. Myocardial strain by Doppler echocardiography. Validation of a new method to quantify regional myocardial function. *Circulation.* 2000;102(10):1158-64.
- Sarvari SI, Haugaa KH, Zahid W, Bendz B, Aakhus S, Aaberge L, et al. Layer-specific quantification of myocardial deformation by strain echocardiography may reveal significant CAD in patients with non-ST-segment elevation acute coronary syndrome. *JACC Cardiovasc Imaging.* 2013;6(5):535-44.
- Eek C, Grenne B, Brunvand H, Aakhus S, Endresen K, Smiseth OA, et al. Strain echocardiography predicts acute coronary occlusion in patients with non-ST-segment elevation acute coronary syndrome. *Eur J Echocardiogr.* 2010;11(6):501-8
- DeLong ER, DeLong DM, Clarke-Pearson DL. Comparing the areas under two or more correlated receiver operating characteristic curves: a nonparametric approach. *Biometrics.* 1988;44(3):837-45.
- Santos NSSD, Vilela AA, Barretto RBM, Vale MPD, Rezende MO, Ferreira MC, et al. Applicability of Longitudinal Strain of Left Ventricle in Unstable Angina. *Arq Bras Cardiol.* 2018;110(4):354-61.